

EXPERIMENTAL SUBSTANTIATION OF SELECTING THE PRODUCT FOR SANITATION OF ABDOMINAL CAVITY IN ACUTE GENERALIZED PERITONITIS

State Institution 'The Institute for general and emergency surgery of the National Academy of Medical Sciences of Ukraine', Kharkiv

The work has studied morphological and ultrastructural changes in the mesothelium of rat peritoneum and bacterial contamination after sanitation of abdominal cavity by 0.3% solution of H₂O₂ and Decasan in experimentally simulated generalized peritonitis. It was estimated that application of 0.3% solution of H₂O₂ exerts pronounced local irritating action on the tissues and mesothelium of the peritoneum and intensifies acute peritonitis and slightly reduces the levels of bacterial contamination of the peritoneum. Decasan exhibits high efficacy against bacterial flora and does not exert local irritating action on the tissues and mesothelium of the peritoneum; the product also significantly reduces the level of the bacterial contamination of the abdominal cavity.

Key words: acute peritonitis, peritoneum, mesothelium, hydrogen peroxide, Decasan.

The recent decades saw no substantial improvement of immediate results of treatment for postoperative peritonitis [3, 4]. Currently the use of antibiotics in systemic antibiotic therapy lacks its former effect due to the increasing number of multi-resistant organisms [1, 5]. In this connection, the high-quality sanitation of abdominal cavity becomes increasingly important; the adequacy of sanitation largely determines the course of the disease, as well as the patterns and the incidence of complications [2, 6]. There are numerous studies of bacteriological efficacy evaluation of various products for sanitation of abdominal cavity; at the same time, there are no dependable data concerning the damaging influence of antiseptics on the tissues available in either domestic or international literature.

The aim of this study is comparative evaluation of antibacterial activity and morphological changes in the mesothelium of rat peritoneum after sanitation of abdominal cavity with a number of antiseptics in experimentally simulated generalized peritonitis at various times from the onset of the disease.

Materials and Methods.

The study is based upon the results of the experiment in 16 rats Wistar rats weighing 160-180 g. The surgeries were performed under intramuscular anaesthesia with Ketalex (ketamine) 12.5 mg per 100 g of rat body weight. The ani-

mals were kept and cared for in the vivarium of the Institute in accordance with the provisions of the Strasbourg conference. Peritonitis was modelled in the animals by ligation of the dissected appendix, which was intentionally left in the abdominal cavity. Repeated laparotomy and removal of appendix was performed in 16-18 hours. The further volume of interventions depended on the objectives for each of the groups. The animals were divided into three groups. Group 1 (control) group: abdominal cavity was only dried and other actions were not taken. Group 2: after elimination of the source of peritonitis abdominal cavity was irrigated twice with solutions of sodium chloride 0.9% and hydrogen peroxide 3% at the ration of 9:1 (0.3% solution of hydrogen peroxide). Group 3: after elimination of the source of peritonitis abdominal cavity was irrigated twice with Decasan (0.02% solution of decamethoxin). In 8 hours repeated laparotomy was performed with sampling of peritoneal tissues for histological and electron microscopic studies. Bacteriological sampling was performed before and after sanitation of the abdominal cavity. For histological studies pieces of peritoneum were fixed in 10% neutral formalin. Then the material was subject to standard passage through alcohols of increasing concentrations, Nikiforov liquid (96% alcohol and diethyl ether in 1:1 ratio) and chloroform, after which the material was embedded in paraffin. Serial sections

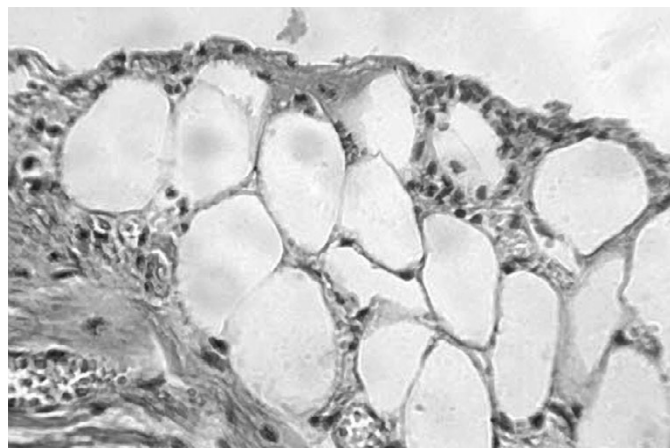


Fig. 1. The peritoneum of a rat from Group P1. Acute suppurative fibrinous peritonitis, plethoric vessels, moderate swelling of the mesothelium. Stained with hematoxylin and eosin. $\times 200$.

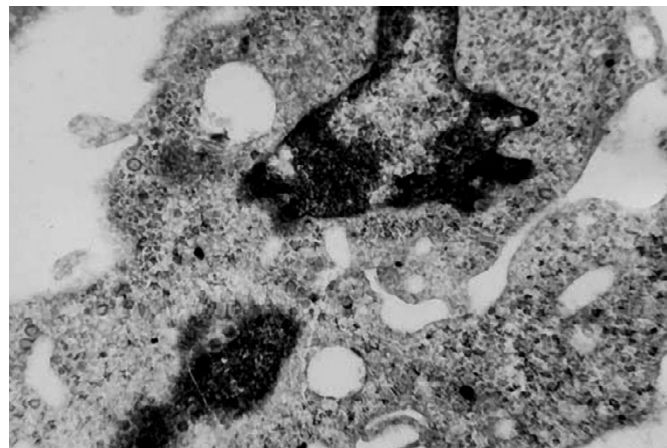


Fig. 2. The ultrastructure of mesothelial cells in the peritoneum of a rat from Group 1. Deep invaginations of the nuclear membrane, chromatin condensation. $\times 38\ 000$. Contrasted with lead citrate.

of the thickness of 4-5 μ m were made of the blocks made in the above fashion. The preparations were stained with hematoxylin and eosin. Each case was subject to microscopic evaluation. Immediately upon excising, the fragments of tissues for electron microscopy were placed in a drop of fixing fluid and refined. Then the tissue for preliminary fixation was transferred into the 2.5% buffered solution of glutaraldehyde for 2-3 hours at the temperature of 4°C. At the end of the preliminary fixation the tissue was washed in buffer solution and placed for final fixation into 1% buffered solution of osmium tetroxide for 2-3 hours at the temperature of 4°C. Dehydration was performed in alcohols of increasing concentrations and acetone.

The tissues were impregnated with a mixture of epoxy resins (Epon-Araldite) according to conventional techniques. Polymerisation of the blocks was performed in a thermostat at the temperature of 60°C during two days. Ultrathin sections were obtained from the resulting blocks using the UMTP-6 ultramicrotome, which were subsequently mounted on electrolytic mesh and, after contrasting with lead citrate, the sections were examined under the electron microscope EMW-100BR at the accelerating voltage of 75 kV. The objective of the microbiological assay was to quantify the content of organisms in the abdominal cavity, which was expressed in CFU/mL.

Results and Discussion

Group 1 (control). On macroscopic examination the visceral peritoneum is hyperaemic, with foci of haemorrhages. A large number of fibrinous deposits and films are visualized on the surface of the peritoneum and intestinal loops. Moderate accumulations of purulent exudate are seen between intestinal loops; the intestinal wall is flaccid and does not tear under tension. The mesothelium is moderately oedematous; the cellular cytoplasm is foamy, the nuclei are moderately hypochromic (see Fig. 1.).

In electron microscopy the nuclei of mesothelial cells were irregular in shape; the nuclear membrane formed deep and shallow invaginations. The perinuclear spaces were unevenly dilated and had the appearance of electron-transparent vesicles. Multiple foci of lysis of the nuclear membrane were frequently observed. The granules of decondensed chromatin were diffusely scattered in the central region of the nuclear matrix (see Fig. 2.).

Quantitative assay of the microflora in the peritoneal exudate has demonstrated that the baseline quantity in all groups was

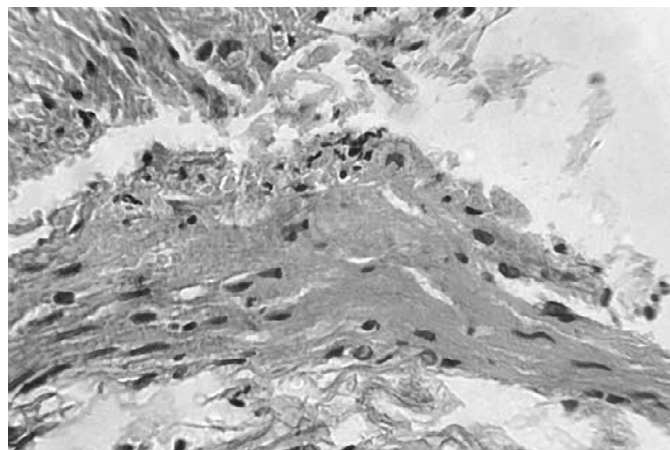


Fig. 3. The peritoneum of a rat from Group 2. Acute suppurative fibrinous peritonitis, loosening of the fibrous elements of the peritoneum, slight leukocyte-macrophage infiltration. Stained with hematoxylin and eosin. $\times 200$.

50×10^6 CFU per 1 mL (lg 7.7).

Group 2 (sanitation with 0.3% solution of hydrogen peroxide). On macroscopic examination visceral peritoneum is moderately hyperaemic, with fine foci of haemorrhages. Insignificant fibrinous deposits and solitary loose films are visualized on the surface of the peritoneum and intestinal loops. Moderate accumulations of serous exudate are seen between intestinal loops; the intestinal wall is dense and does not tear under tension. The mesothelium is dramatically swollen, mostly desquamated in whole layers; the cellular cytoplasm is slightly eosinophilic, foamy, the nuclei are hypochromic (see Fig. 3.).

After sanitation of abdominal cavity with hydrogen peroxide solution, the ultrastructural organization of organelles in mesothelial cells of the peritoneum continues to exhibit destructive lesions, typical for peritonitis. Moreover, the ultrastructural lesions in the organelles of the mesothelial cells of the peritoneum were often worse in terms of depth and expression than those in the cells prior to exposure to hydrogen peroxide. The nuclear membrane formed quite deep invaginations with focal dilations of the perinuclear space. The condensed nuclear chromatin is assembled in osmiophilic clumps located on the periphery of the nuclear membrane. Electron-transparent areas filled with freely laying granules of decondensed chromatin were formed in the nuclear matrix. The cytoplasm around the nucleus was virtually void of organelles and had low electron density and rough lumpy structure (see Fig. 4.).

After sanitation of the abdominal cavity by solutions of hydrogen peroxide (0.3%) the amount of microflora reduced by an order: 5×10^6 (lg 6.7) CFU/mL.

Group 3 (sanitation of abdominal cavity by Decasan solution). On macroscopic examination the visceral peritoneum is hyperaemic, with foci of haemorrhages. A small number of fibrinous deposits and films are visualized on the surface of the peritoneum and intestinal loops. Small accumulations of purulent exudate are seen between intestinal loops; the intestinal wall is flaccid and does not tear under tension. The mesothelium is moderately oedematous at places; the cellular cytoplasm is foamy, the nuclei are moderately hypochromic (see Fig. 5.).

After simulation of peritonitis and subsequent sanitation with Decasan solution, the ultrastructural architectonics of the mesothelial cells of the peritoneum demonstrates a trend towards increased levels of reparation intracellular processes.

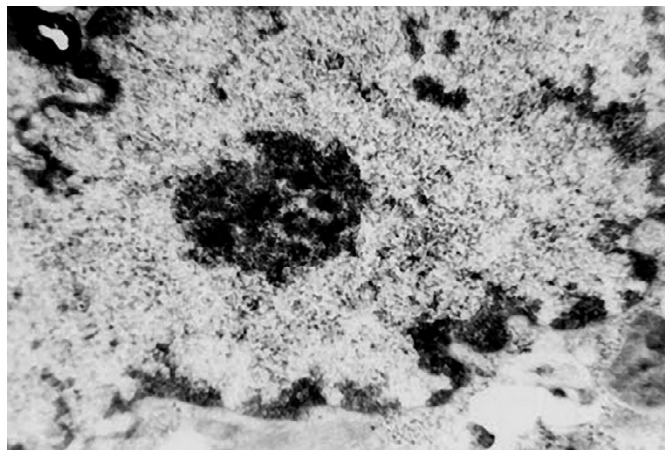


Fig. 4. The ultrastructure of the mesothelial cells of the peritoneum in rats of Group 1. Invaginations and focal lysis of the nuclear membrane, an electron-transparent area in the centre of nuclear matrix. $\times 52\,000$. Contrasted with lead citrate.

The nuclei of mesothelial cells become round and slightly inverted in shape; the number and the depth of invaginations of the nuclear membrane decreases. The width of perinuclear spaces is somewhat decreased. The number of perinuclear spaces is somewhat decreased. The number of decondensed chromatin granules increases, which are more evenly distributed across the square of nuclear section. The condensed form of chromatin is situated adjacent to the nuclear membrane (see Fig. 6.).

In the 3d series of animals, in which sanitation of abdominal cavity was performed with Decasan, microbial contamination of the content of abdominal cavity was $10-100 \times 10^3$ (lg=4-5, 4.5 on the average) CFU/mL.

When analysing the morphological status of peritoneal mesothelium after sanitation of experimentally simulated peritonitis, it should be noted that the selected antiseptics demonstrate different efficacy both in terms of their impact on development of inflammation (peritonitis) and concerning the mesothelial elements. In sanitation of the inflammatory focus with 0.3% solution of H_2O_2 the microscopic examination reveals severe dystrophy, oedema and desquamation of the mesothelium. Thus, already in 20-24 hours the above pathological changes of the tissues of peritoneum and mesothelium are consistent in pattern and severity with the findings in non-sanitized peritonitis (control group). This is because the main mechanism of action of hydrogen peroxide is that in contact with the tissues, it breaks down into water and molecular oxygen (this reaction is caused by the enzyme catalase, contained in all organic matter). The oxygen produced oxidises not only microbial organisms, but also exerts aggressive influence on the organic compounds of the surrounding healthy tissues, thereby causing destruction thereof. The damaged tissues have significantly impaired ability to hold suture material (due to loosening and oedema), and massive desquamation of mesothelium aggravates exudation and facilitates the development of adhesions. The submicroscopic architectonics of the mesothelial cells of the peritoneum retains destructive changes, manifested as focal lysis of the nuclear membrane, focal destruction of mitochondrial membranes and cristae of mitochondria, as well as destruction of cytoplasmic membrane, which is manifesting of intracellular catabolic processes. In terms of structure the development of catabolic processes is supported by the presence of mesothelial cells of secondary lysosomes in the cytoplasm. A pronounced mitochondrial dysfunction remains. Based on the observed ultrastructural changes in mesothelial cells, it can be concluded that sanitation of

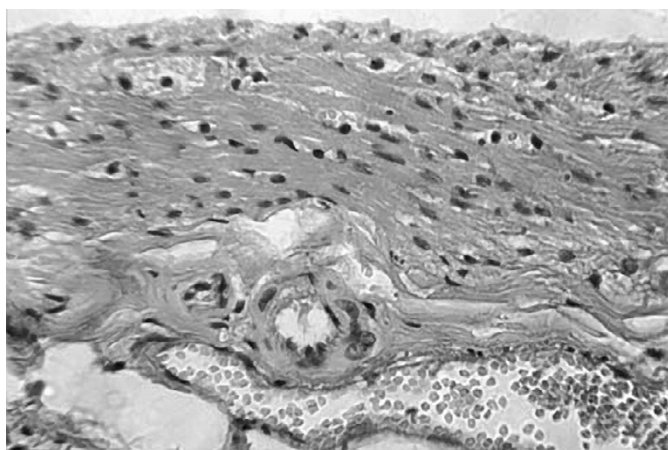


Fig. 5. The peritoneum of a rat from Group 3. Acute suppurative fibrinous peritonitis, moderate diffuse inflammatory infiltration, plethoric veins. **Stained with hematoxylin and eosin. $\times 200$.**

abdominal cavity with hydrogen peroxide does not promote reparation processes on the submicroscopic level.

According to our research, the best results and the highest efficacy of sanitation of abdominal cavity are observed in application of Decasan. Decasan does not have any significant local irritating, resorptive and sensitizing properties; its application does not impede tissue healing and does not leave permanent tissue marks. Decasan does not cause oedema of peritoneum and omentum, which ensures good fixation of suture material; by sparing action on peritoneal mesothelium the drug minimizes the development of adhesions in the postoperative period. The ultrastructural remodelling of peritoneal mesotheliocytes, found in peritonitis after sanitation with Decasan solution is evident of the trend towards activation of intracellular metabolic processes. This is indirectly confirmed by decreased quantity of the foci of lysis of the membranes of granular endoplasmic reticulum and mitochondria, as well as the development of moderate hypertrophy of lamellar cytoplasmic Golgi complex, and the absence of secondary lysosomes in the cytoplasm.

Conclusions.

1. Sanitation of the abdominal cavity in acute diffuse peritonitis by 0.3% solution of H_2O_2 is an ineffective method to prevent and treat secondary complications of diffuse peritonitis. Application of 0.3% solution of H_2O_2 exerts pronounced local irritating action on the tissues and peritoneal mesothelium, thus intensifying the signs and symptoms of peritonitis, decreasing the efficacy of fixation of suture material and facilitating the development of adhesions in the postoperative period.
2. Sanitation of abdominal cavity in acute diffuse peritonitis by 0.02% solution of decamethoxin (Decasan) is the most effective method to prevent and treat secondary complications of diffuse peritonitis. Decasan manifests high efficacy against bacterial flora and does not exert local irritating action on the tissues and mesothelium of the peritoneum, decreases the oedema of the peritoneum and omentum, which ensures good fixation of suture material and minimizes the development of adhesions in the postoperative period by sparing influence upon peritoneal mesothelium.

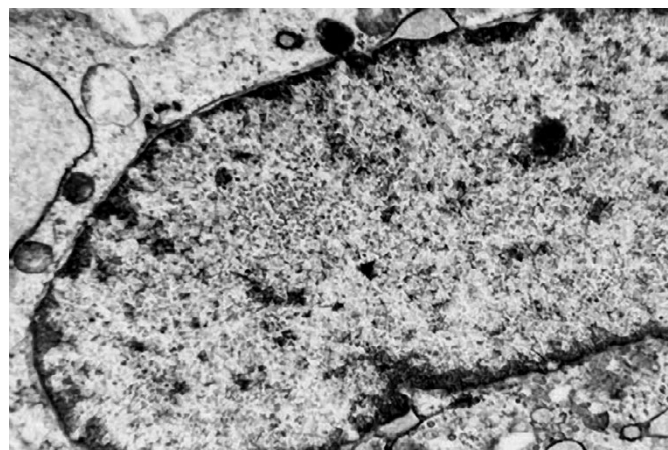


Fig. 4. The ultrastructure of the mesothelial cells of the peritoneum in rats of Group 1. Invaginations and focal lysis of the nuclear membrane, an electron-transparent area in the centre of nuclear matrix. $\times 52\,000$. Contrasted with lead citrate.

Abstract

EXPERIMENTAL SUBSTANTIATION OF SELECTING THE PRODUCT FOR SANITATION OF ABDOMINAL CAVITY IN ACUTE GENERALIZED PERITONITIS

V.V. Boyko, V.K. Logachev, N.A. Remneva, M.E. Tymchenko, V.P. Nevzorov, O.A. Golovina

The work has studied morphological and ultrastructural changes in the mesothelium of rat peritoneum and bacterial contamination after sanitation of abdominal cavity by 0.3% solution of H₂O₂ and Decasan in experimentally simulated generalized peritonitis. It was estimated that application of 0.3% solution of H₂O₂ exerts pronounced local irritating action on the tissues and mesothelium of the peritoneum and intensifies acute peritonitis and slightly reduces the levels of bacterial contamination of the peritoneum. Decasan exhibits high efficacy against bacterial flora and does not exert local irritating action on the tissues and mesothelium of the peritoneum; the product also significantly reduces the level of the bacterial contamination of the abdominal cavity.

Key words: acute peritonitis, peritoneum, mesothelium, hydrogen peroxide, Decasan.

References:

1. The choice of sanitation solutions and methods of suturing of the abdominal wall in generalized purulent peritonitis [Text] / S.O. Kosulnikov, S.I. Karpenko, S.A. Tarnapolskyi, K.V. Kravchenko // Ukrainian Journal of Surgery. – 2009. – Issue No. 3. – p. 95-98.
2. Endogenous toxemia in acute peritonitis and its treatment / V.O. Kavin, Yu.L. Popovych, N.Ye. Kovalchuk, V.M. Fedorak // Hospital Surgery. – 2009. - Issue No.1. – p. 49-51.
3. The mistakes of selecting the tactics of surgical treatment of generalized peritonitis [Text] / V.S. Savelyev, M.I. Filimonov, P.V. Podachin, S.V. Chubchenko // The Annals of Surgery. – 2008. - Issue No.1. – p. 26-32.
4. Peritonitis / [Savelyev V.S., Gelfand B.R., Filimonov M.I. et al.]; ed. by V.S. Savelyev – Moscow: Literra, 2006. – 208 p.
5. Ren J.A. [et al.] Management of tertiary peritonitis in the patients complicated with intestinal fistula. – Zhonghua Wei Chang Wai Ke Za Zhi. – 2006. – Vol. 9 (4). – P. 284-286.
6. Sepsis and multiple organ dysfunction / E.A. Deitch, J.L. Vinsent, W.B. Saunders // London, 2002. – 370 p.

The article received on 01.03.2011